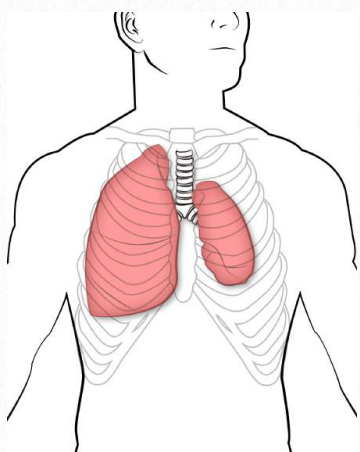


A. PULMONARY ULTRASOUND FOR PNEUMOTHORAX EVALUATION

Assessment of pneumothorax via ultrasound is essentially done by observing the normal motion of the visceral pleura (over the lungs) interfacing or “sliding” with the parietal pleura (see picture below). When a pneumothorax occurs, the air between the visceral and parietal pleura will scatter the transmitted sound, thus disrupting its return to the transducer. This results in a fixed, “motionless” parietal pleura on the ultrasound screen. Realize that this occurs because of the air, so the lung may still be ventilatable, but the air will prevent one from seeing the “sliding” of the lung being ventilated. This is why ultrasound is more sensitive than a chest x-ray. Also, because the pleural line is usually centimeters below the chest wall, a high-frequency (5.0–10.0 MHz) linear probe provides the most detailed image of the pleural line. However, any transducer can be used, realizing that with the lower frequency probes your image quality will be poorer.



Once the pleural line is identified, there are two critical findings, lung sliding and comet tail artifacts, that essentially guarantee that the visceral and parietal pleura are opposed, thus ruling out pneumothorax in that space. Comet tails are linear reverberation artifacts that originate at the pleural line and are caused by the bouncing back and forth of sound between the dense fibrous tissue of the visceral and parietal pleura “together”. This comet tail reverberation artifact is only possible if the pleural layers are in opposition and there is no air between them (i.e. pneumothorax) scattering the sound and preventing this phenomenon. Therefore, *the presence of B lines suggest against the possibility of a pneu-*

mothorax. It is important to note that the comet tails also represent a differentiation of density of the lung parenchyma and this fact is used to identify and quantify air-space disease. This is discussed further in the next chapter. Lung sliding is the visualization of the shimmering, sliding motion of the visceral and parietal pleura with respiration. This is caused by the expansion and contraction of the chest wall with breathing. Again, this motion alteration of the pleural line and sliding can only be visualized when the two pleural layers are in opposition. Air between the visceral and parietal pleura will scatter the transmitted sound, thus disrupting its return to the transducer and ensuring only the fixed parietal pleura will be seen.

M-mode is the motion mode displaying moving structures along a single line in the ultrasound beam. M-mode imaging can show diagnostic findings for PTX in a still image representation. The “barcode” sign is seen with a lack of lung sliding and indicates air in the pleural space so the fixed chest wall musculature *looks similar* to the lung pleura (they are *both static*). Whereas, the “seashore” sign depicts normal pleural sliding by showing the closely opposed visceral and parietal motion with respiration (static chest wall with distorted or sanding picture of lung pleura motion).

One finding on pulmonary ultrasound that is thought to be almost universally specific for pneumothorax is called the “lung point sign.” This sign occurs at the point where the partial PTX has started to separate the pleura and reattachment or detachment of the pleura is visible. This results in the screen showing half of the image having lung sliding and comet tails, while the other half of the image shows lack of lung sliding or a fixed parietal pleura with no comet tails. This lung point can be followed around the chest wall to get a sense of how large the pneumothorax is. Finally, the “lung pulse”, or visualization of the pleural line “beating” with the underlying heart rate, is a marker of opposed visceral and parietal pleura, because transmitted heart pulsations can only be seen if there is no pneumothorax or air separating the pleural layers.

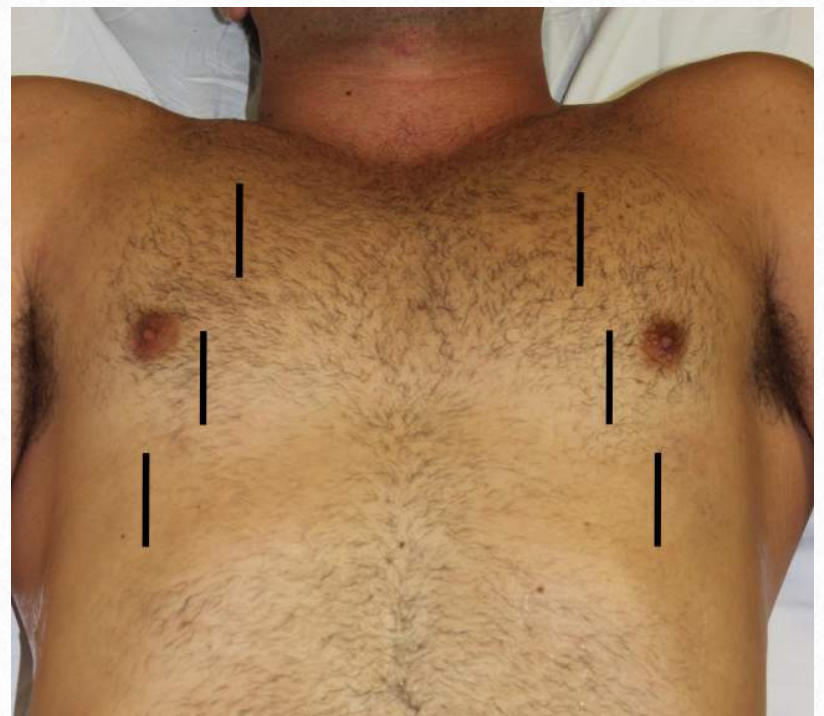
It is important to note that patients with absence of lung sliding secondary to a pneumothorax should also not demonstrate findings of the ultrasound wavelength penetrating into the lung parenchyma (because the air interface should cause reflection). Therefore signs of the ultrasound penetrating into the lung tissue, such as the presence of B lines (see next

chapter), suggest that there is NOT pneumothorax. To summarize, absence of lung sliding with B lines suggests against a pneumothorax. It is important to note that the lack of sliding alone is not sufficient to make a diagnosis of pneumothorax. This can be secondary to: apnea, bronchial intubation/obstruction, pleural adhesion, and large infiltrates.

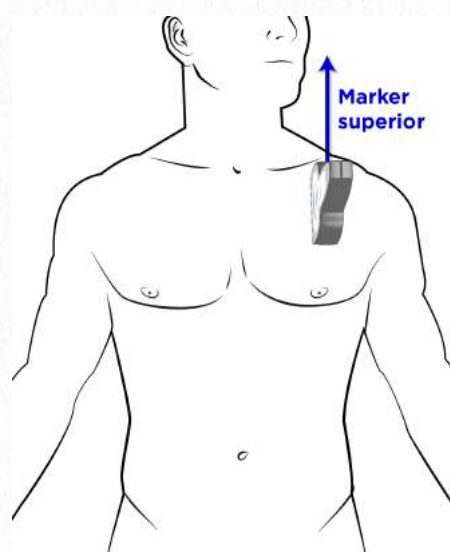
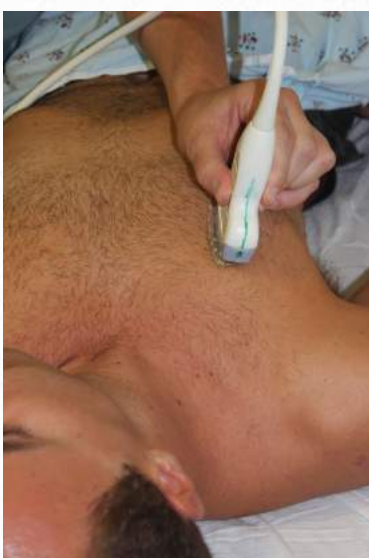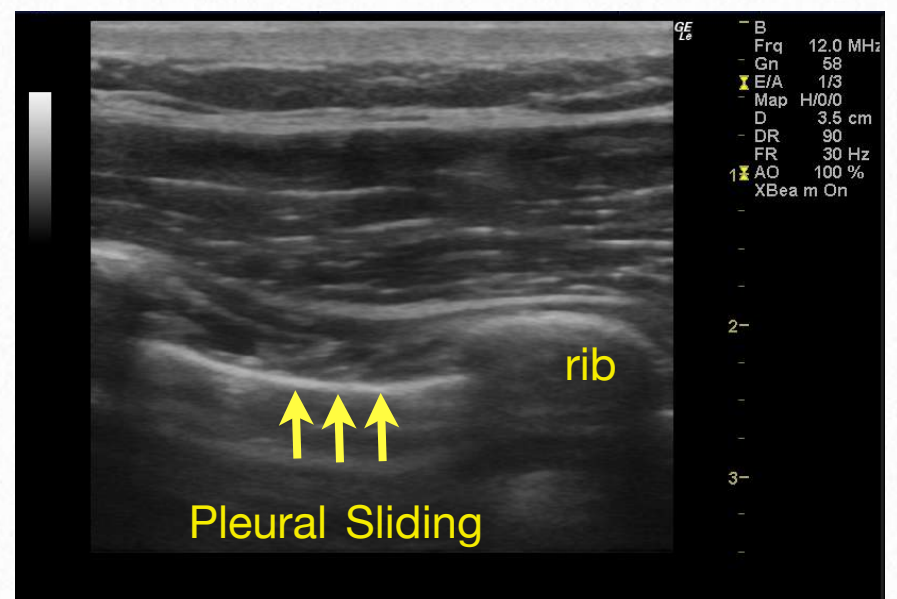
Patient Position: Supine usually and then one would scan the most anterior segments of the chest. If the patient is in another position, realize that one should scan the most the most anterior areas (where one would think air would go). The transducer is placed on the chest wall, starting in the third or fourth intercostal space in the mid-clavicular line in a supine patient or the second intercostal space in an upright patient (see below), and the rib shadows are visualized with the pleural line identified just deep to the rib shadow. It is important to identify the rib in cross section initially, because patients with deep chest walls can have intercostal fat or pectoralis muscle fascia that can mimic the pleural line. Once the pleural line is identified, there are two critical findings, lung sliding and comet tail artifacts (discussed above), that essentially guarantee that the visceral and parietal pleura are opposed just underneath the probe footprint, thus ruling out pneumothorax in that space.

the pleural line scanning the anterior segments in 3 sections for both sides (total of 6 locations, see picture below). These six regions, delineated by the anterior and posterior axillary lines, should be systematically examined: upper and lower parts of the anterior, lateral, and posterior chest wall.

Lung Pleura Examination Windows: Always remember PTX will form at the highest (most anterior) point in the chest.

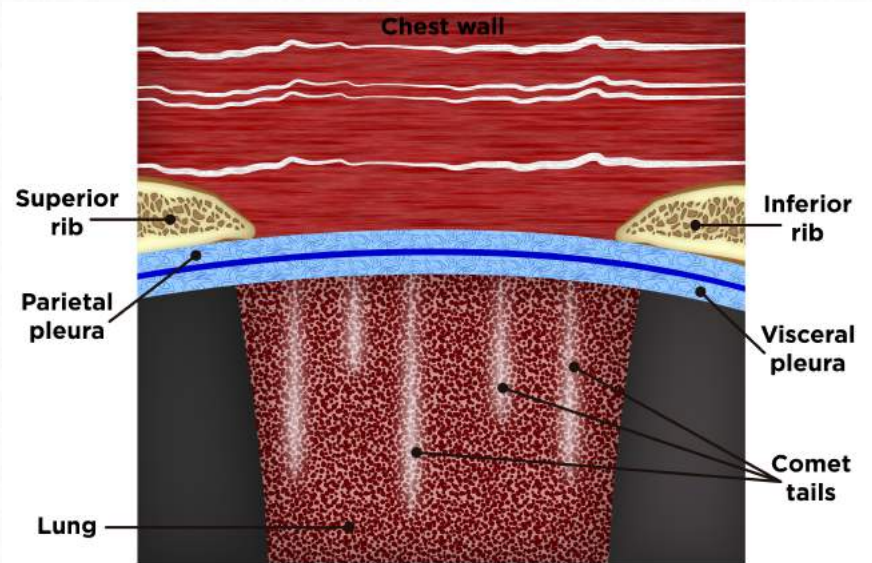


Normal Exam


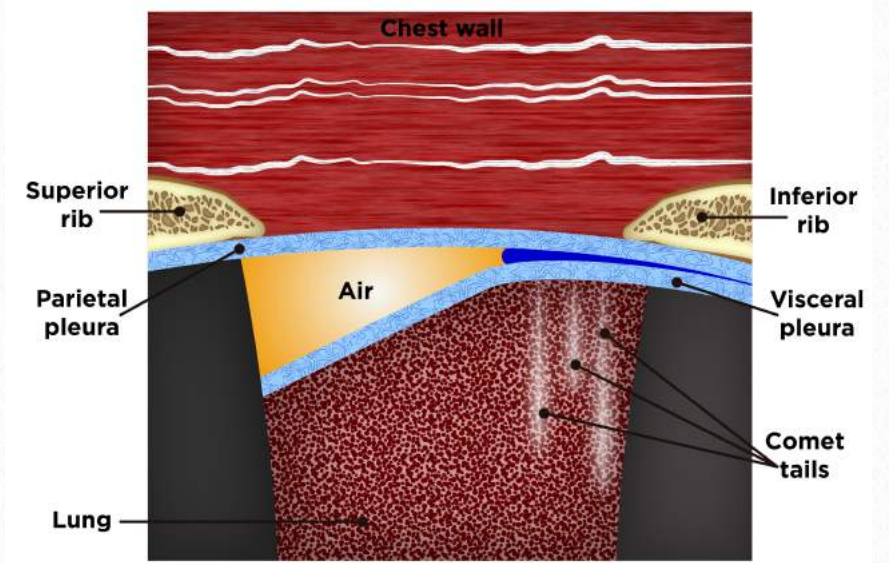


Probe Position: Probe (linear is best) is placed on the anterior chest wall along the mid-clavicular line and then followed along the pleural line (see below). The indicator should be at the 12 o'clock position, perpendicular to the ribs. The transducer is oriented to scan between the ribs, as ribs block the transmission of ultrasound. Ideally one should have two ribs in view, one on each of the lateral sides of the ultrasound image. One should move the transducer longitudinally along

Normal PI



Lung Point



Findings of a Pneumothorax

